

Producing false clownfish (*Amphiprion ocellaris*) male broodstock by administering 17 α -methyltestosterone to protandrous hermaphrodite juveniles

^{1,2}Muhammad Y. Abduh, ^{2,3}Nguyen Phuc Thuong, ²Ambok B. Abol-Munafi, ^{1,4}Nor H. Norazmi-Lokman

¹ Faculty of Fisheries and Food Sciences, Universiti Malaysia Terengganu, 21030 Kuala Nerus, Malaysia; ² Institute of Tropical Aquaculture, Universiti Malaysia Terengganu, 21030 Kuala Nerus, Malaysia; ³ Department of Aquatic Biology and Resources Management, Faculty of Fisheries, Nong Lam University of Ho Chi Minh City, Vietnam; ⁴ Fisheries and Aquaculture Centre, Institute for Marine and Antarctic Studies, University of Tasmania, Taroona, Tasmania, Australia. Corresponding author: N. H. Norazmi-Lokman, lokhakim@umt.edu.my

Abstract. Failure to distinguish the sex of hatchery produced fish hinders *Amphiprion ocellaris* broodstock development in captivity as they need to be paired for breeding. Therefore, this study explored the possibility of producing male *A. ocellaris* broodstock by exposing the hermaphrodite juveniles to 17 α -methyltestosterone (MT). Two sets of trials were conducted and compared where hermaphrodite *A. ocellaris* juveniles (3.5-5.5 cm total length) was exposed to MT via immersion (1, 2 and 4 ppm, 0 ppm as control) and oral treatments (30, 60 and 120 mg kg⁻¹ feed, 0 mg as control). The immersion trials lasted for 15 days while the oral treatment was conducted for 2 months. Gonad samples of three fish from each treatment were sampled for histological studies at the end of the experiments. The remaining fish were reared for another two more months before their gonad were sampled to observe the gonad development post hormone exposure. Comparison between all treatments for both trials showed that immersing *A. ocellaris* juveniles in 1 ppm of MT showed the most promising result in developing male broodstock. At the end of the trials, the gonads were in the early transitional stages of masculinisation. Testicular cells at different stages such as spermatogonia, spermatocyte and spermatid were observed in all samples. Two months post treatment observation shows that the gonads from this treatment still exhibits successive development of testicular cells compared to others.

Key Words: 17 α -methyltestosterone, androgen, monosex, gonads, spermatogenesis, false clownfish.

Introduction. Between 1.5 and 2 million people worldwide are believed to keep marine aquaria (Wabnitz et al 2003). The trade which supplies this hobby with live marine animals is a global multimillion-dollar industry where the marine fish's price is estimated to be at US\$ 400 to 600 per pound (Ladisa et al 2017) with the total value exceeding US\$ 300 million (Palmtag 2017). The marine ornamental industry mainly consists of wild caught coral reef fishes where less than 10 percent of marine species are cultured. According to FAO, the Coral Triangle region which includes Indonesia, Malaysia, Papua New Guinea and the Philippines is the main resource of marine ornamental fishes where it was estimated that at least 85 percent of marine aquarium fish traded in the United States come from this region (Ladisa et al 2017).

Till date, only 24 marine ornamental species are regularly available in the market although it was reported that 134 marine ornamental species have been successfully bred for commercial purpose (Pouil et al 2020). The false clownfish (*Amphiprion ocellaris*) is one of the first species to be commercially bred in captivity and the demand is high especially since the release of Disney's 2003 animation 'Finding Nemo' (Militz & Foale 2017). *A. ocellaris* is protandrous, meaning that all individuals develop first into males

and then possibly into females later in life (Nakamura et al 2006; Miura et al 2008). Most of the females are slightly larger in size than the males (Iwata et al 2008; Abol-Munafi et al 2011a; Iwata & Manbo 2013). If the female broodstock dies, the male broodstock will change into female, while the largest nonbreeders will develop into active male, while the other nonbreeders remain sexually inactive (Madhu et al 2010; Nguyen et al 2019). However, it is possible that some of these nonbreeders might migrate to other anemone host to mate with each other if the dominant pair outlived them in the current anemone (Hattori 2012).

The demand for *Amphiprion* sp. as ornamental fish has increased but due to deterioration of its natural habitat and the effects of over-fishing, their numbers have drastically decreased. To replenish its natural population, captive breeding of these anemonefish in artificial conditions for mass production has been undertaken (Liew et al 2006; Kumar et al 2012; Dhaneesh et al 2012). One of the proposed current methods for the mass production of clownfish is to directly produce male and female broodstock in captivity. Sexing hatchery produced or wild caught *A. ocellaris* juveniles for brood stock development at times can be troublesome as it is almost impossible to identify male and female by naked eye observation on its morphology (Phuc Thuong et al 2017). The usual sexing method used is by its body size where females are usually larger than male broodstocks (Buston 2003; Iwata et al 2008; Abol-Munafi et al 2011a). However, this method is inaccurate (Abol-Munafi et al 2011b). Experimentation in broodstock production would render a better plan in controlling *A. ocellaris* populations or for inducing sex inversion at certain periods under specific conditions as well.

Hormone sex reversal has been widely used in the aquaculture industry for producing monosex population (Kato et al 2001; Hasheesh et al 2011; Singh 2013). Among the reproductive steroids, 17α -methyltestosterone (MT) is the most commonly used androgen to masculinize fishes (Pandian & Sheela 1995; Pandian & Kirankumar 2003; Hasheesh et al 2011) due to its reliability (Kefi et al 2012). Several methods of steroid administration are available (Gale et al 1999) but immersion or oral treatments are preferred due to their efficiency (Pandian & Sheela 1995; Donaldson & Devlin 1996). The duration of hormone treatment needed to achieve maximum effects varies from species. In general, for immersion treatment the duration ranges from several hours (Gale et al 1999; Wassermann & Afonso 2003) to several weeks (Kim et al 1997; Arslan & Phelps 2003; Turan et al 2006; Kang et al 2008). Feeding treatment generally lasts between 30 and 150 days (Kuo et al 1988; Blázquez et al 1995; Al-Ablani & Phelps 1997; Navarro-Martín et al 2009). The dosage of the hormone is also species specific which means it differ between species. Dosages used range from 200 to 6400 $\mu\text{g L}^{-1}$ for immersion treatments (Piferrer & Donaldson 1991), and 0.5-1200 mg kg^{-1} for feeding treatments (Pandian & Sheela 1995). Previous study has reported that *A. ocellaris* remain at the juvenile stage with both undeveloped ovarian and testicular tissues (Abol-Munafi et al 2011a). Therefore, this study aims to assess the effects of 17α -methyltestosterone (MT) administration on the gonadal development of *A. ocellaris* juveniles thus paving the way for producing male *A. ocellaris* brood stocks in a short period of time and easing brood stock management.

Material and Method. The experiment was conducted at the Marine Hatchery Unit of the Institute of Tropical Aquaculture (AKUATROP), Universiti Malaysia Terengganu for 12 months. Moral and ethical aspect of the research such as animal handling, use of anaesthesia and minimum amount of fish needed for valid statistical analysis complied with the Research Ethics Guidelines of Universiti Malaysia Terengganu.

Sample source. One hundred and sixty false clownfish (*Amphiprion ocellaris*) (3.5-5.5 cm in total length) juveniles were collected from the wild using hand nets by scuba diving at the waters of UMT Marine Research Station, Bidong Island, Terengganu located off of the East coast of Malaysia. The fish were packed in plastic bags filled with sea water and oxygen (at 1:3 ratio) and then transported to the hatchery within a few days of capture. There was no mortality recorded during transportation. The fish were acclimatized in the hatchery aquaria for 2 weeks before hormone treatment.

Experimental design

1) *Immersion method.* MT powder (Argent Laboratories Inc., Philippines) was weighed to the requirement of each concentration and then mixed with 20 mL of 95% ethanol (Hmbg Chemicals). The solutions were then poured into 4 aquaria with one hormone treatment per aquarium. The aquaria were filled with 50 L of seawater and aerated to spread the hormone evenly. The concentrations of MT used were 1, 2, and 4 ppm with a control treatment consisting of only 20 mL of 95% ethanol. Each aquarium was filled with 20 juvenile *A. ocellaris* that were chosen randomly. Food pellets (Nutrafin Max Marine Complete Food, Rolf C. Hagen (U.S.A) Corp) were given three times every day and the water were changed every 24 hours. The hormone treatment was replenished with the water change daily for a 15-day period and then the fish were reared for 2 months without hormone administration. Parameters such as survival rates and gonad histology were taken at the end of the experiment. For the gonad histology studies, three fish were dissected for histological examination at the beginning of the experiment before exposure to the MT treatment. Then, 3 more fish from each treatment were dissected at the end of the 15-day experimental period and again after 2 months of rearing post-exposure.

2) *Feeding method.* The juveniles were weaned to feed on pellet feed (Nutrafin Max Marine Complete Food, Rolf C. Hagen (U.S.A) Corp) for about 3-4 weeks before the start of the experiment. Treated diets were fed three times per day at 0830 h, 1230 h and 1630h until satiation. Wastes were siphoned out of the tanks every day before first feeding. Four aquaria were filled with 100 L of seawater with aeration. The concentration of MT that was used is 30, 60 and 120 mg kg⁻¹ feed. First, the pellet feed was crushed to dust. The hormones were dissolved in 100 mL of 70% ethanol (Hmbg Chemicals) using a volumetric flask, sprayed onto the feed using an aspirator, and were left overnight to dry. The control diets were sprayed with just the 70% ethanol. Each aquarium was filled with 20 juveniles which were chosen randomly. The hormone treatment was done in 2 months and then the fish were reared for another 2 months where the fish were fed with untreated diets. During this period, the water quality was kept at salinity of 30-35‰, temperature of 26-29°C, pH of 7.5-8.5 and dissolved oxygen of 5.5-6.5 mg L⁻¹. Parameters such as survival rates and gonad histology were taken at the end of the experiment. Three fish were dissected at the end of the 2 months experiment period from each treatment and again at 2 months post feeding method experiment.

Histological studies. For each experiment, the gonad structure of treated *A. ocellaris* juveniles were observed by histological study. The histological study was conducted using routine paraffin histology following Drury & Wallington (1967), Hinton (1990) and Kiernan (1990) with modifications. The samples were dehydrated during tissue processing using the Leica (TP 1020) tissue processor and embedded in paraffin wax. The embedded samples were trimmed and sectioned into 4-5 µm thick slices using a standard microtome. Each of the sections was dewaxed, dried, and stained with hematoxylin-eosin. The slides containing the sections were then mounted before being observed using an Advanced Research Microscope equipped with a Motic camera (Japan, Nikon Eclipse 80i) and NIS-Elements D 2.30 software. The identification of the gonad structure was done based on Groman (1982) and Chinabut et al (1991).

The volume percentage rate of testicular tissues in a gonad was randomly calculated into three sections at 200x magnification captured images. The formula used for determination was as follows:

$$\text{Testicular rate} = \frac{\text{No. of testicular cells}}{\text{No. of testicular cells} + \text{No. of ovarian cells}} \times 100$$

Statistical analysis. All data were tested for normality (Shapiro-Wilk normality test) and when normality was achieved, the percentages of testicular cells were analysed by using one-way Analysis of Variance (ANOVA). Significant differences between treatments were determined using Duncan's post hoc test and the level of significance difference was set at $p < 0.05$. All data were analysed using IBM SPSS Statistics software (version 17).

Results. Prior to the hormonal treatment, the juvenile *A. ocellaris* showed ambisexual gonads with both spermatocytes and oocytes. The testicular cells appeared to be interspersed throughout the ovary and both cells types remained undeveloped (Figure 1).

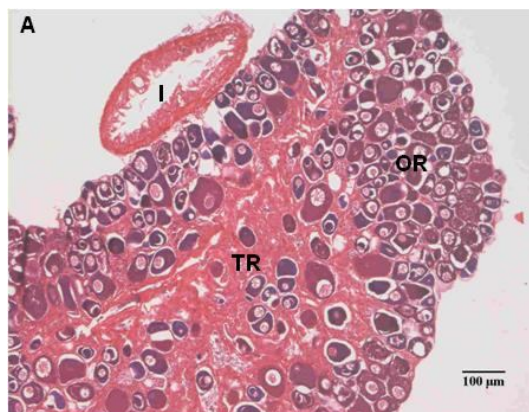


Figure 1. Gonadal cross-sections of *A. ocellaris* juvenile before treatment with 17 α -methyltestosterone. TR, testicular region; I, intestine; OR, ovarian region (200X magnifications).

Immersion method. At the end of the 15 days immersion method experiment, all of the gonads in each treatment group showed a marked development of the testicular tissues. The testicular tissue area showed spermatogenic cells in all stages; including spermatogonia, spermatocytes, spermatids and spermatozoa (Figure 2). However, no data could be gathered from fish treated at the 4 ppm MT exposure group because all the fish died 2 days after treatment.

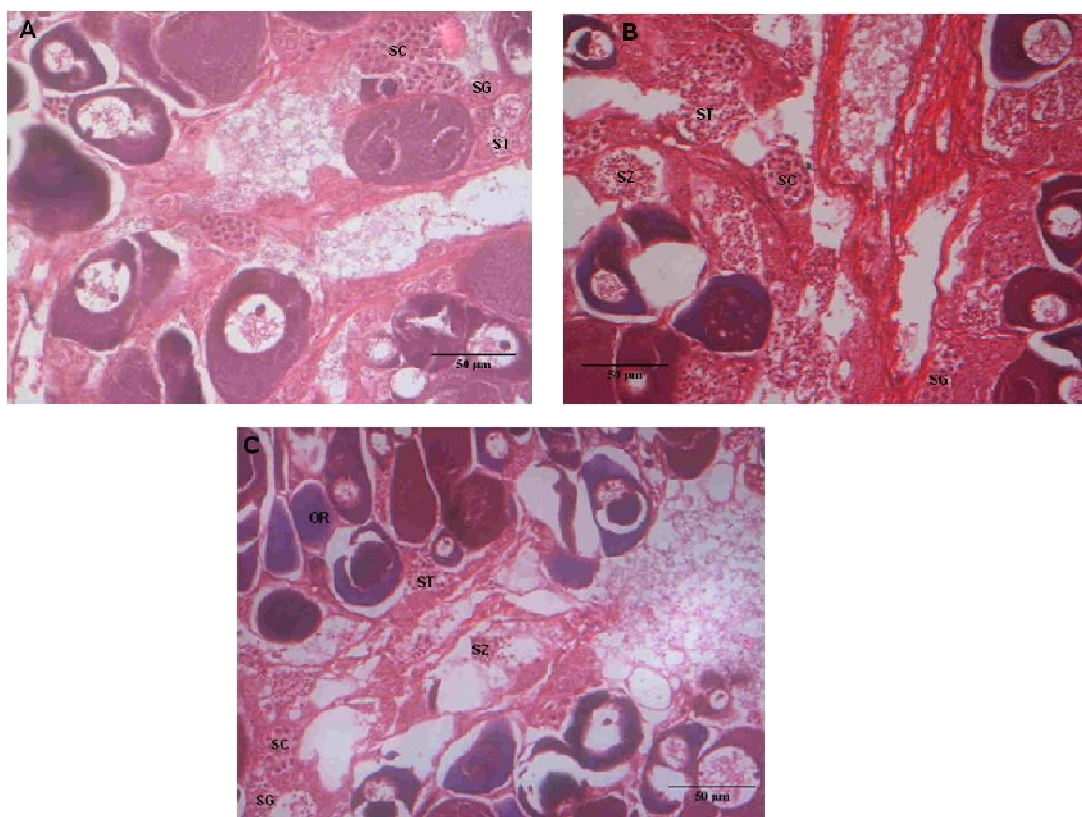


Figure 2. Gonadal cross section of *A. ocellaris* juvenile after 15 days treatment with 17 α -methyltestosterone showing (A) gonads of control fish, (B) gonad of 1 ppm treated fish and (C) gonad of 2 ppm treated fish. OR, ovarian region; SG, spermatogonia; SC, spermatocytes; ST, spermatid; SZ, spermatozoa. (A-C, 400X magnifications)

After 2 months of rearing post-treatment, the gonads from the control and 1 ppm treated fish remained ambisexual with both testicular and ovarian cells. Cysts of spermatogonic cells, including spermatogonia and spermatocytes, were found scattered throughout the ovarian region. The ovarian cells consisted primarily of young oocytes with the most developed oocytes in the perinuclear region. However, the gonads from the 2 ppm treated fish showed the development of ovarian tissues (pre-vitellogenic oocytes and vitellogenic oocytes). The testicular tissue decreased in its percentages, indicating that the fish were beginning to undergo a male-to-female sex change (Figure 3).

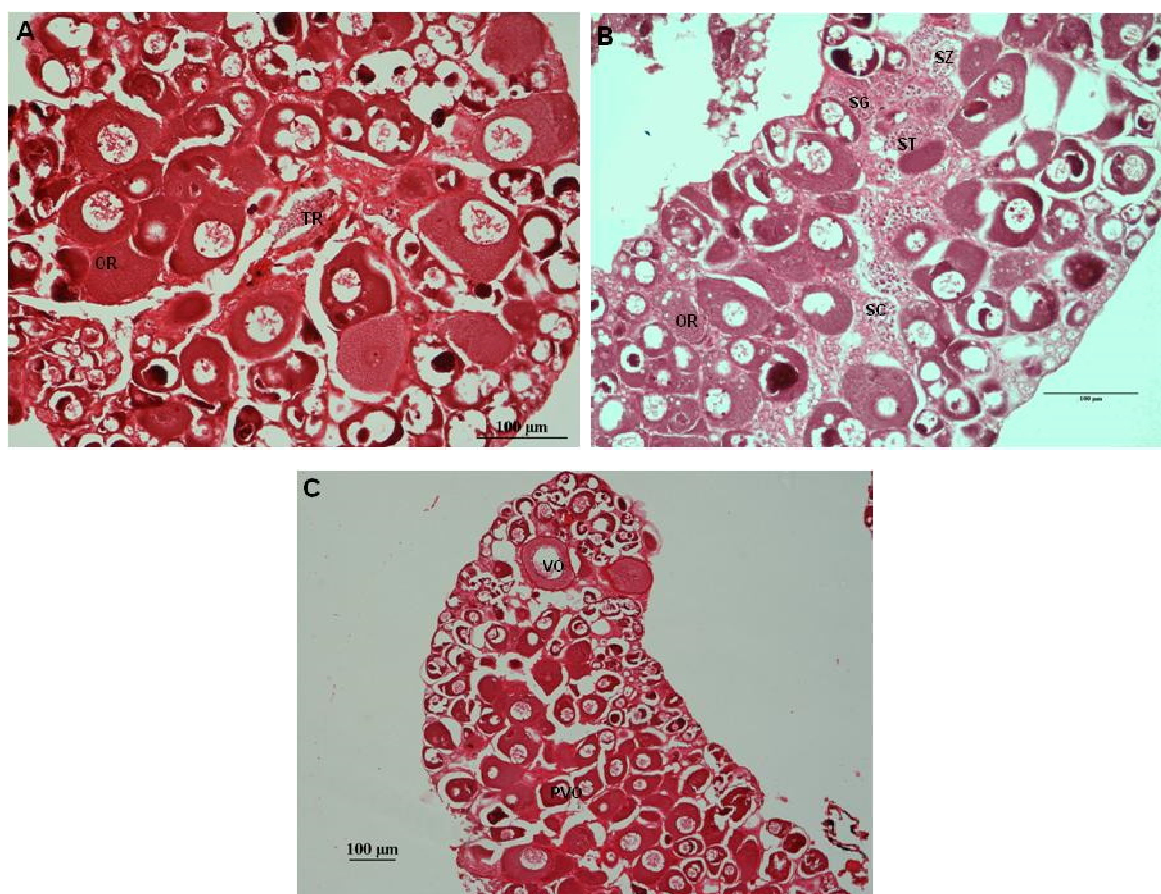


Figure 3. Gonadal cross section of *A. ocellaris* juveniles 2 months post-exposure to 15 days of 17 α -methyltestosterone showing (A) gonads of control fish, (B) gonad of 1 ppm treated fish and (C) gonad of 2 ppm treated fish. OR, ovarian region; SG, spermatogonia; SC, spermatocytes; ST, spermatid; SZ, spermatozoa; PVO, pre-vitellogenic oocytes; VO, vitellogenic oocytes. (A-C, 200X magnifications).

The highest survival rate (95%) was observed in fish treated with MT at the concentration of 1 ppm while the lowest survival rate (50%) was observed in fish exposed to the 2 ppm concentration (Table 1).

Table 1
Survival rate of juvenile *A. ocellaris* after 15-days 17 α -methyltestosterone exposure

Group of treatment	No. fish examined	Survival rate (%)
Control	20	100
1 ppm	20	95
2 ppm	20	50
4 ppm	20	0

The percentage of the testicular cells of treated and control fish was also calculated at the end of the experiment where the percentage of testicular region in the treated fish is higher than in the control. The percentage varied significantly (Table 2). There was

significant difference between the control group with the 1 ppm treated fish in the volume of testicular tissues in the gonad (LSD: $p < 0.05$; Table 2). However, there were no significant difference in the percentage of testicular region between the control group and the 2 ppm treated fish.

Table 2

The percentage of testicular tissues in gonad of *A. ocellaris* during immersion of 17 α -methyltestosterone

Group of treatment	After 15 days of MT immersion	After 2 months post-hormone exposure
Control	63.45 ± 4.92^a	54.86 ± 6.69^a
1 ppm	75.6 ± 5.29^b	55.9 ± 19.81^a
2 ppm	61.89 ± 6.32^a	0

Means (\pm SE) within a column followed by different superscript letters were significantly different ($p < 0.05$).

Feeding method. At the end of the 2-month of feeding method experiment, the samples from the control fish shows diminishing of testicular cells. The ovotestes were dominated by ovarian cells, mostly pre-vitellogenic oocytes. However, in some samples, there are still testicular cells in every phase from spermatogonia to spermatozoa (Figure 4a). Ovotestes from fish fed with 30 and 60 mg kg^{-1} of MT shows development of testicular cells where all the phase of spermatogenesis was found intermixed with the ovarian cells (Figure 4b and 4c). Meanwhile, the ovotestes from fish fed with 120 mg kg^{-1} of MT show development on the ovarian cells. It progresses until the vitellogenic oocytes stage (Figure 4d). However, there were still testicular cells in all stages, which are indeed decreasing.

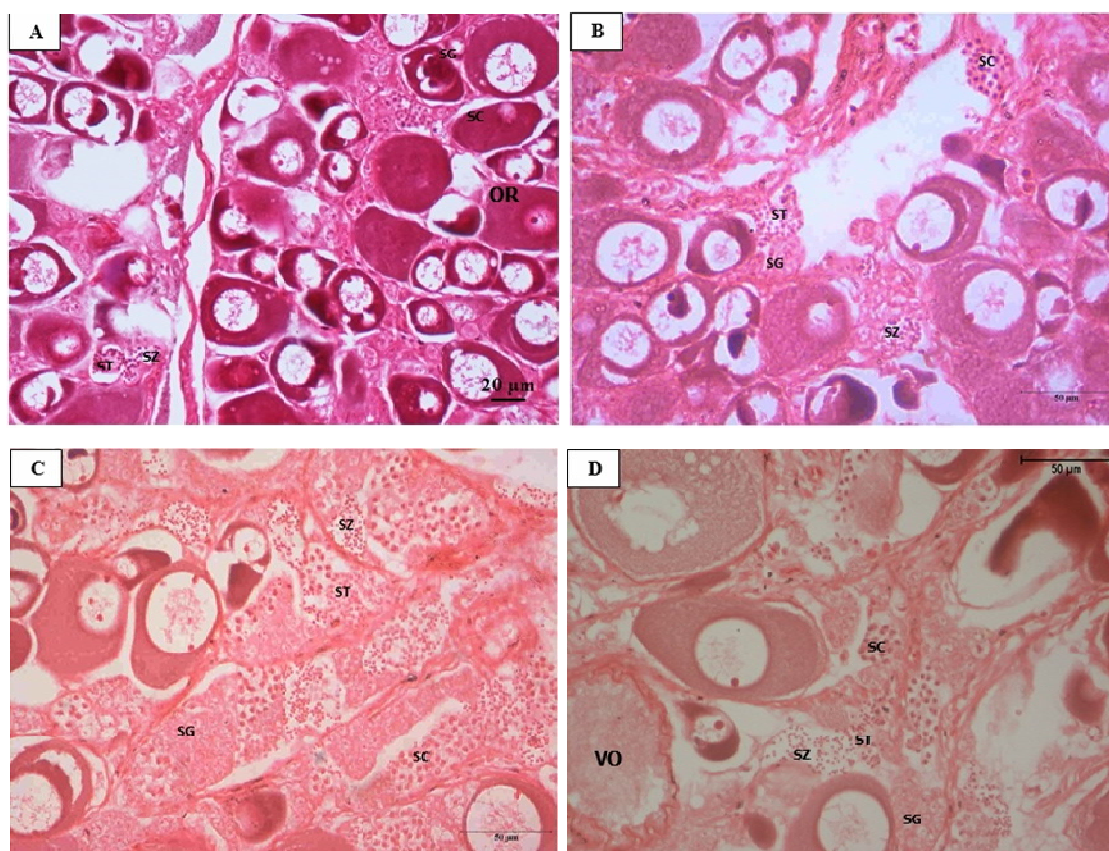


Figure 4. Gonadal cross-sections of *A. ocellaris* juvenile after 2 months treatment with 17 α -methyltestosterone treated diets showing (A) gonads of control fish, (B) gonad of 30 mg kg^{-1} treated fish and (C) gonad of 60 mg kg^{-1} treated fish and (D) gonad of 120 mg kg^{-1} treated fish.

OR, ovarian region; VO, vitellogenic oocytes; SG, spermatogonia; SC, spermatocytes; ST, spermatid; SZ, spermatozoa. (A-D, 400X magnifications).

After 2 months of rearing post-treatment, only the ovotestes of the control fish showed spermatogonia and spermatid cells (Figure 5a). All MT treated fish (30 mg kg⁻¹, 60 mg kg⁻¹ and 120 mg kg⁻¹) showed development of the ovarian cell until the vitellogenic oocytes (Figure 5b, 5c and 5d).

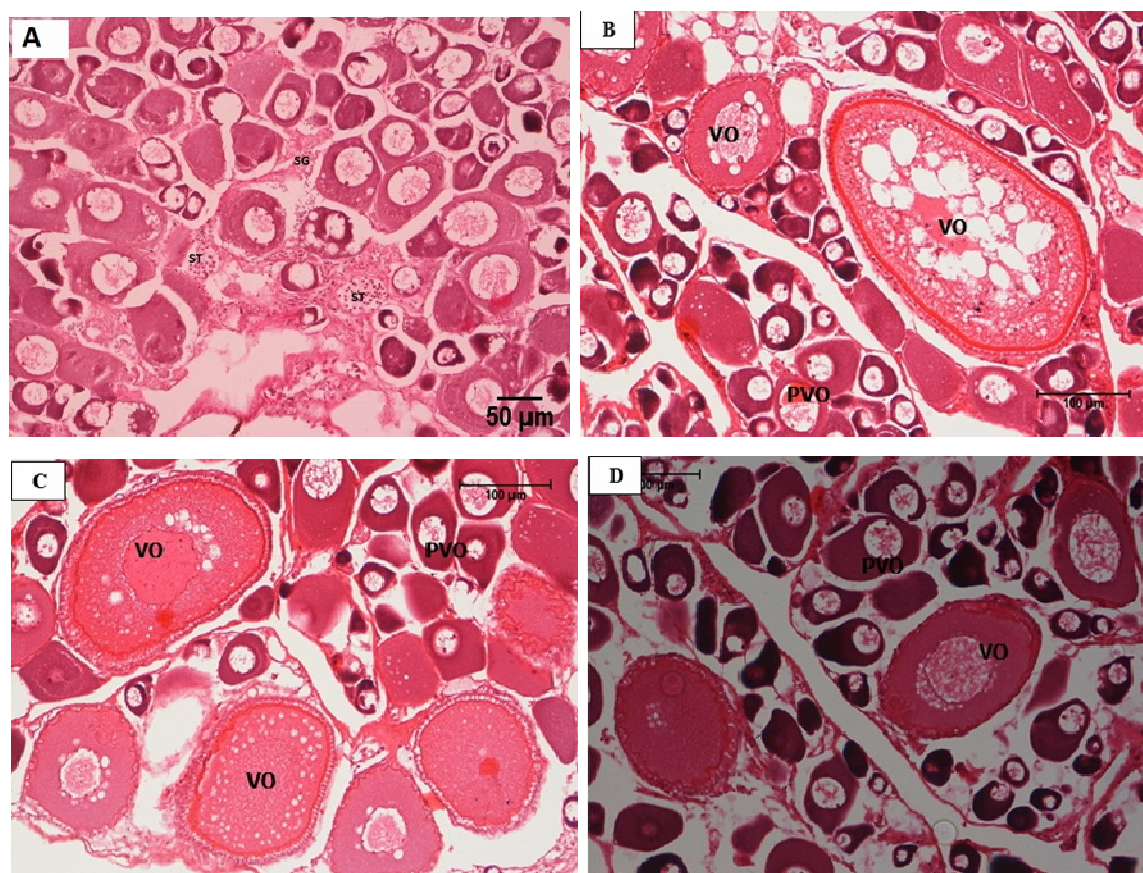


Figure 5. Gonadal cross-sections of *A. ocellaris* juvenile 2 months post treatment with 17 α -methyltestosterone treated diets showing (A) gonads of control fish, (B) gonad of 30 mg kg⁻¹ treated fish and (C) gonad of 60 mg kg⁻¹ treated fish and (D) gonad of 120 mg kg⁻¹ treated fish. OR, ovarian region; PVO, pre-vitellogenic oocytes; VO, vitellogenic oocytes; SG, spermatogonia; SC, spermatocytes; ST, spermatid; SZ, spermatozoa. (A-D, 200X magnifications).

The highest survival rate (100%) was shown by fish treated with 30 and 60 mg kg⁻¹ diets while the lowest survival rate (70%) was observed in fish treated with 120 mg kg⁻¹ diet (Table 3). The percentage of the testicular cells of control and MT treated fish was also calculated at the end of the experiment. There was significant difference between the control group with the 60 mg kg⁻¹ treated fish at the end of the 2 months feeding method experiment (LSD: $p < 0.05$; Table 4). However, there were no significant differences in the percentage of testicular region between all treatments at 2-month post feeding method experiment as only control fish showed testicular cells.

Table 3
Survival rate of juvenile *A. ocellaris* after 2 months treatment with MT treated diets

Group of treatment	No. fish examined	Survival rate (%)
Control	20	85
30 mg kg ⁻¹	20	100
60 mg kg ⁻¹	20	100
120 mg kg ⁻¹	20	70

Table 4

The percentage of testicular tissues in gonad of *A. ocellaris* during oral administration of MT

Group of treatment	After 2 months of MT diet administration	After 2 months post-hormone exposure
Control	42.86±6.89 ^a	45.61±5.31
30 mg kg ⁻¹	49.25±7.13 ^a	0
60 mg kg ⁻¹	79.22±3.32 ^b	0
120 mg kg ⁻¹	0	0

Means (±SE) within a column followed by different superscript letters were significantly different ($p < 0.05$).

Discussion. The male gonad of *Amphiprion* sp. contains both active testicular tissues and immature ovarian tissues (Miura et al 2003; Rattanayuvakorn et al 2006; Miura et al 2008; Iwata et al 2008; Abol-Munafi et al 2011a). In the false clownfish (*Amphiprion ocellaris*), the testicular region of the ovotestis is intermixed with the ovarian region but there are no clear boundaries between these cells. This condition differs from the gonads of other *Amphiprion* species such as in *Amphiprion polymnus* (Rattanayuvakorn et al 2006), *Amphiprion melanopus* (Godwin & Thomas 1993), *Amphiprion frenatus* (Brusle-Sicard & Reinboth 1990) and *Amphiprion clarkii* (Miura et al 2003) where the testicular cells were peripheral in the ovotestis and the ovarian cells are more centrally located.

A. ocellaris can be assumed as dyginic, where two developmental ways to mature female can be seen. Dyginic is a term to explain when primary females differentiate ovaries from the juvenile phase and remain functional throughout adult life, while secondary female changes from an initial male phase (Yeung 2000). In this case, the largest juveniles in a group can mature and take the responsibility as the functional male in the presence of a functional female, or in another situation, it can develop directly as a functional female without having to change to male first, if no larger fish are present. This is also shown in studies on *A. clarkii* (Hattori & Yanagisawa 1991; Yeung 2000) and *A. melanopus* (Godwin 1992).

The process of sex change in *Amphiprion* species were shown in *A. polymnus* and *A. melanopus* by Rattanayuvakorn et al (2006) and Godwin (1992), respectively. The sex change in these species is characterized by degeneration of male germ cells, deposition of yellow-brown pigment and the formation of advance vitellogenic oocytes. These yellow-brown pigments were always found in the middle of testicular cells in the gonad and separated from pre-vitellogenic oocytes. Extensive maturation on the testicular cells then occurred where all the cells were spermatozoa with no trace of early stage of spermatogenesis. The continued development of spermatogenic cells proceeds until it was replaced with the proliferation of oogonia. The gonads become immature ovary, being composed primarily of pre-vitellogenic oocytes. The fish were considered female once vitellogenic oocytes were found. It took between 45 and 100 days for *A. melanopus* to change sex while *A. polymnus* took 6-12 months. The shortest reported completion of sex change for the genus *Amphiprion* is 26 days for an individual *A. bicinctus* (Fricke 1983). Two other species, *A. akallopisos* and *A. clarkii*, have been observed to change sex in less than 63 days and less than 5 to 6 months, respectively (Fricke & Fricke 1977; Moyer & Nakazono 1978).

In the immersion method experiment, all treated fish except for control and 4 ppm treated group, showed a positive effect of MT to their gonads after the 15 days treatment period. Each treated gonad showed a development of testicular cells from different stages such as spermatogonia, spermatocytes, spermatid and spermatozoa. These testicular cells were more abundant and larger (in terms of area size) in the MT-treated fish that survived. The histological data indicates that there was more growth and maturation activity in the testicular cells than the ovarian cells. Most of the ovarian cells found in the gonads of the treated fish were young oocytes and the most developed oocytes were only in the pre-vitellogenic oocytes. Referring to Yeung (2000) report on *A. clarkii* reproductive biology, based on the evidence of the testicular tissues observed, all males treated with MT can be considered as spawning capable males.

Interestingly, after 2 months of rearing post-15 day MT treatment, the only fish to still exhibit testicular development were from the 1 ppm MT exposure groups. There were some testicular cells in the control fish though some of them show the dismissing of testicular cells. This result for the control fish may show that the fish are on the verge of sex conversion from male to female as observed by Rattanayuvakorn et al (2006). However, in all gonads examined from the fish in the 1 ppm MT-treated fish there was no evidence of a decrease in the testicular cells and still no activity in the ovarian cells. There was still the presence of testicular cells such as spermatogonia, spermatocytes, spermatids and spermatozoa in the gonads of the 1 ppm treatment group. However, the gonads of the 2 ppm MT-treated fish showed developmental activity in the ovarian cells. There was evidence of both pre-vitellogenic and vitellogenic oocytes. This ovarian development may have occurred because the fish were undergoing a sex conversion to female. According to Turan et al (2006), successful sex reversal by immersion in low concentration of MT for prolonged periods was accomplished in guppy (*Poecilia reticulata*), and also in medaka (*Oryzias latipes*) (Kang et al 2008), black crappie (*Pomoxis nigromaculatus*) (Arslan & Phelps 2003), and in Nile tilapia (*Oreochromis niloticus*) (Gale et al 1999; Wassermann & Afonso 2003). This might explain the observation made in this study.

Fish treated with MT orally showed an interesting observation on the gonad histology. At the end of 2 months period, only samples from 30 and 60 mg kg⁻¹ MT treated fish show the development of testicular cells. The samples from the control group show diminishing of testicular cells. The percentage of testicular tissues between the control and 60 mg kg⁻¹ MT treated fish showed a significant difference. Meanwhile, the samples from 120 mg kg⁻¹ MT treated fish shows that it is in the beginning of transitional phase from male to female. There are vitellogenic oocytes appear in the ovotestes, the testicular cells are fast developing, and majority of the testicular tissues are spermatid and spermatozoa. However, 2 months post hormone treatment, all the samples from the MT treated fish show development of the ovarian tissues. The gonad consists mainly of pre-vitellogenic oocytes and vitellogenic oocytes. There are no spermatogenic cells found inside the gonads. Based on Yeung (2000), these fish can be categorized as inactive females. Meanwhile, for the control fish, there were no major differences between the two observation periods. It can be concurred that the use of oral MT administration does not show a promising result. Nonetheless, other studies have shown a success in producing males via oral MT administration. Al-Ablani & Phelps (1997) were the first to report the success of masculinizing (*Pomoxis nigromaculatus*) using the same hormone and administration method. Others successful sex reversal using MT treated diets are coho salmon (*Oncorhynchus kisutch*) (Goetz et al 1979) and European sea bass (*Dicentrarchus labrax*) (Blázquez et al 1995; Navarro-Martin et al 2009).

It is believed the long exposure period and high dosage of MT somehow led to the effects of paradoxical feminization hence the low testicular tissues and high ovarian tissue observed in the histological study (Piferrer 2001; Pandian & Kirankumar 2003). This common effect has been observed to occur not only in fish but also in amphibians and reptiles (Piferrer 2001). There is a high chance of considerable amount of MT leaking into the rearing water during the dietary treatment. MT dissociates from the treated food quickly. According to Contreras-Sanchez (2001), high value of MT remained in the water for at least 30 minutes after food consumption. This shows that, even after the fish consumed all the food given, there is still high level of MT in the water. Therefore, it is possible that in closed or semi-closed systems like the one used in this study, the fish are exposed to MT not just from the diet, but also through immersion. The high amount of MT above physiological levels together with a long exposure period might have interacted with the aromatase gene expression thus resulting in high production of estrogen which promotes the development of ovarian cells in the gonad of oral treated fish (Papoulias et al 2000; El-Greisy & El-Gamal 2012; Stell & Moller 2017).

Synthetic 17MT can be aromatized to a 17 α -methylestradiol (Ankley et al 2001; Hornung et al 2004). The enzyme cytochrome P450 aromatase catalyzes the synthesis of estrogens from androgens (Simpson et al 1997; Pandian & Kirankumar 2003). Aromatase is found in the brain, gonads, and other peripheral tissues including the placenta and the

adipose tissue in mammals (Simpson et al 1997). Callard et al (1981) reported that the level of this enzyme (cytochrome P450) in the brain of teleost is 100-1,000-fold higher than in the brain of mammals. Aromatase was attributed to the regulation of reproductive behavior (Pasmanik & Callard 1988). In goldfish, *Carassius auratus*, aromatase levels were highest during the time of spawning and lowest during periods of reproductive inactivity (Pasmanik & Callard 1988).

According to Crim et al (1981), MT is an aromatizable synthetic androgen that can be metabolized into estrogenic compounds. In many cases, the use of higher dosages of MT for short periods has been observed to cause paradoxical feminization and usage of MT for longer time periods has been shown to cause sterilization (Pandian & Sheela 1995). This problem can be reduced with the use of nonaromatizable steroids such as 17 α -methyl-dihydrotestosterone (MDHT) (Piferrer & Donaldson 1991) and with the use of aromatase inhibitor (AI) that is mixed with MT to inhibit the conversion of MT to estrogen (Li et al 2006; Singh 2013; Ranjan et al 2015). Piferrer et al (1993) found that MDHT is twice more potent than MT in masculinizing female Chinook salmon. MT can be naturally converted to a less active form and simply has a faster rate of clearance from the body, which may be the reasons for the lack of a consistent effect in MT treatment (Gale et al 1999). There might also be a bit of biasness when treating the fish orally. The amount of hormone received by each fish depends on the consumption of treated diet as well as the concentration of androgens in the diets (Pandian & Sheela 1995; Budd et al 2015). Feed acceptance might vary among individual juveniles and can result in size differences. It is obvious that bigger fish might prevent feed consumption by smaller fish (Beardmore et al 2001). In regard to this study, the better option for producing males are through immersion method due to the short treatment period, high survival, low hormone usage and prolong masculinization effect which is more viable for commercial production.

The observation made in this study showed that male produced after MT treatment can be paired with females and used directly for breeding or it can be reared up till 2 months prior to breeding especially those treated via immersion method. This can ease brood stock management of this species in captivity. Further studies are recommended to assess the reproductive fitness of hormone treated fish.

Conclusions. This study demonstrates that it is possible to achieve high rates of masculinization in *A. ocellaris* using both immersion and feeding administration. Nonetheless, it is suggested that the administration of MT using immersion method at the dose of one ppm to juveniles is the best method to produce male broodstocks due to the lowest level of mortality and the existence of testicular cells even after 2 months post-MT exposure besides being less laborious.

Acknowledgements. This study was supported financially by the Ministry of Sciences, Technology and Innovations (MOSTI) of Malaysia under the E-Science project no. 05-01-12-SF0057. The authors thank Mr. Syahnon of the Institute of Tropical Aquaculture and the SCUBA crews, Universiti Malaysia Terengganu (UMT) for their assistance.

References

- Abol-Munafi A. B., Norazmi-Lokman N. H., Asma N. A., Sarmiza S., Abduh M. Y., 2011a Histological study on the gonad of the protandrous anemonefish (*Amphiprion ocellaris*). Journal of Animal and Veterinary Advances 10(22): 3031-3036.
- Abol-Munafi A. B., Sarmiza S., Norazmi-Lokman N. H., Abduh M. Y., 2011b Sexual dimorphism on the morphometric characteristics of pink skunk clownfish, *Amphiprion perideraion*. Indian Journal of Science and Technology 4(S8): 287-288.
- Al-Ablani S. A., Phelps R. P., 1997 Sex reversal in black crappie *Pomoxis nigromaculatus*: effect of oral administration 17 α -methyltestosterone on two age classes. Aquaculture 158: 155-165.
- Ankley G. T., Jensen K. M., Kahl M. D., Korte J. J., Makynen E. A., 2001 Description and evaluation of a short-term reproduction test with fathead minnow (*Pimephales promelas*). Environmental Toxicology and Chemistry 20(6): 1276-1290.

- Arslan T., Phelps R. P., 2003 Production of monosex male black crappie, *Pomoxis nigromaculatus*, populations by multiple androgen immersion. *Aquaculture* 234:561-573.
- Beardmore J. A., Mair G. C., Lewis R. I., 2001 Monosex male production in finfish as exemplified by tilapia: applications, problems, and prospects. *Aquaculture* 197(1-4):283-301.
- Blázquez M., Piferrer F., Zanuy S., Carillo M., Donaldson E. M., 1995 Development of sex control techniques for European sea bass (*Dicentrarchus labrax* L.) aquaculture: effects of dietary 17 α -methyltestosterone prior to sex differentiation. *Aquaculture* 135:329-342.
- Brusle-Sicard S., Reinboth R., 1990 Protandric hermaphrodite peculiarities in *Amphiprion frenatus* Brevoort (Teleostei, Pomacentridae). *Journal of Fish Biology* 36(3):383-390.
- Budd A. M., Banh Q. Q., Domingos J. A., Jerry D. R., 2015 Sex control in fish: approaches, challenges and opportunities for aquaculture. *Journal of Marine Science and Engineering* 3(2):329-355.
- Buston P., 2003 Size and growth modification in clownfish. *Nature* 424(6945):145-146.
- Callard G. V., Petro Z., Ryan K. J., Claiborne J. B., 1981 Estrogen synthesis *in vitro* and *in vivo* in the brain of a marine teleost (*Myoxocephalus*). *General and Comparative Endocrinology* 43(2):243-255.
- Chinabut S., Limsuwan C., Kitsawat P., 1991 Histology of the walking catfish *Clarias batrachus*. Aquatic Animal Health Research Institute, Bangkok, Thailand, 96 pp.
- Contreras-Sanchez W. M., 2001 Sex determination in Nile tilapia *Oreochromis niloticus*: gene expression, masculinization methods and environmental effects. PhD thesis, Oregon State University, 193 pp.
- Crim L. W., Peter R. E., Billard R., 1981 Onset of gonadotropic hormone accumulation in the immature trout pituitary gland in response to estrogen or aromatizable androgen steroid hormones. *General and Comparative Endocrinology* 44(3):374-381.
- Dhaneesh K. V., Devi K. N., Kumar T. T. A., Balasubramanian T., Tissera K., 2012 Breeding, embryonic development and salinity tolerance of skunk clownfish *Amphiprion akallopisos*. *Journal of King Saud University-Science* 24(3):201-209.
- Donaldson E. M., Devlin R. H., 1996 Uses of biotechnology to enhance production. In: *Developments in aquaculture and fisheries science*. Pennell W., Barton B. A. (eds), Elsevier, 29:969-1020.
- Drury R. A. B., Wallington E. A., 1980 Carlestone's histological technique. 5th edition, Oxford University Press, London, 520 pp.
- El-Greisy Z. A., El-Gamal A. E., 2012 Monosex production of tilapia, *Oreochromis niloticus* using different doses of 17 α -methyltestosterone with respect to the degree of sex stability after one year of treatment. *The Egyptian Journal of Aquatic Research* 38(1):59-66.
- Fricke H., Fricke S., 1977 Monogamy and sex change by aggressive dominance in coral reef fish. *Nature* 266:830-832.
- Fricke H. W., 1983 Social control of sex: field experiments with the anemonefish *Amphiprion bicinctus*. *Zeitschrift für Tierpsychologie* 61(1):71-77.
- Gale W. L., Fitzpatrick M. S., Lucero M., Contreras-Sanchez W. M., Schreck C. B., 1999 Masculinization of Nile tilapia (*Oreochromis niloticus*) by immersion in androgens. *Aquaculture* 178(3-4):349-357.
- Godwin J. R., 1992 The behaviour and physiology of protandrous sex change in the cinnamon anemonefish, *Amphiprion melanopus*. PhD thesis, University of Hawaii, 140 pp.
- Godwin J. R., Thomas P., 1993 Sex change and steroid profiles in the protandrous anemonefish *Amphiprion melanopus* (Pomacentridae, Teleostei). *General and Comparative Endocrinology* 91(2):144-157.
- Goetz F. W., Donaldson E. M., Hunter G. A., Dye H. M., 1979 Effects of 17 β -estradiol and 17 α -methyltestosterone on gonadal differentiation in the coho salmon *Oncorhynchus kisutch*. *Aquaculture* 17:267-278.

- Groman B. D., 1982 Histology of the striped bass. American Fisheries Society, Monograph Number 3, 116 pp.
- Hasheesh W. S., Marie M. A. S., Abbas H. H., Eshak M. G., Zahran E. A., 2011 An evaluation of the effect of 17 α -methyltestosterone hormone on some biochemical, molecular and histological changes in the liver of Nile tilapia *Oreochromis niloticus*. Life Science Journal 8(3): 343-358.
- Hattori A., 2012 Determinants of body size composition in limited shelter space: why are anemonefishes protandrous? Behavioral Ecology 23(3): 512-520.
- Hattori A., Yanagisawa Y., 1991 Life-history pathways in relation to gonadal sex differentiation in the anemonefish, *Amphiprion clarkii*, in temperate waters of Japan. Environmental Biology of Fishes 31(2): 139-155.
- Hinton D. E., 1990 Histological techniques. In: Methods for fish biology. Schreck C. B., Moyle P. B. (eds), American Fisheries Society, Bethesda, USA, pp. 191-211.
- Hornung M. W., Jensen K. M., Korte J. J., Kahl M. D., Durhan E. J., Denny J. S., Henry T. R., Ankley G. T., 2004 Mechanistic basis for estrogenic effects in fathead minnow (*Pimephales promelas*) following exposure to the androgen 17 α methyltestosterone: conversion of 17 α - methyltestosterone to 17 α -methylestradiol. Aquatic Toxicology 66(1): 15-23.
- Iwata E., Nagai Y., Hyoudou M., Sasaki H., 2008 Social environment and sex differentiation in the false clown anemonefish, *Amphiprion ocellaris*. Zoological Sciences 25(2): 123-128.
- Iwata E., Manbo J., 2013 Territorial behaviour reflects sexual status in groups of false clown anemonefish (*Amphiprion ocellaris*) under laboratory conditions. Acta Ethologica 16(2): 97-103.
- Kang I. J., Yokota H., Oshima Y., Tsuruda Y., Shimasaki Y., Honjo T., 2008 The effects of methyltestosterone on the sexual development and reproduction of adult medaka (*Oryzias latipes*). Aquatic Toxicology 87: 37-46.
- Kato K., Hayashi R., Kasuya T., Yamamoto S., Murata O., Kumai H., 2001 Induction of all-male groups in red sea bream, *Pagrus major*, by oral administration of 17 α -methyltestosterone. Aquaculture Science 49(3): 339-345.
- Kefi A. S., Kang'ombe J., Kassam D., Katongo C., 2012 Growth, reproduction and sex ratios in *Oreochromis andersonii* (Castelnau, 1861) fed with varying levels of 17 α -methyl testosterone. Journal of Aquaculture Research and Development 3(8): 1000155.
- Kiernan J. A., 1990 Histological and histochemical methods: theory and practice. 2nd edition, Pergamon Press, 433 pp.
- Kim D. S., Nam Y. K., Jo J. Y., 1997 Effect of oestradiol-17 β immersion treatments on sex reversal of mud loach, *Misgurnus mizolepis* (Gunther). Aquaculture Research 28(12): 941-946.
- Kumar T. T. A., Gopi M., Dhaneesh K. V., Vinoth R., Ghosh S., Balasubramanian T., Shunmugaraj T., 2012 Hatchery production of the clownfish *Amphiprion nigripes* at Agatti island, Lakshadweep, India. Journal of Environmental Biology 33(3): 623-628.
- Kuo C. M., Ting Y. Y., Yeh S. L., 1988 Induced sex reversal and spawning of blue-spotted grouper, *Epinephelus fario*. Aquaculture 74: 113-126.
- Ladisa C., Bruni M., Lovatelli A., 2017 Overview of ornamental species aquaculture. FAO Aquaculture Newsletter 56: 39-40.
- Li G. L., Liu X. C., Lin H. R., 2006 Effects of aromatizable and nonaromatizable androgens on the sex inversion of red-spotted grouper (*Epinephelus akaara*). Fish Physiology and Biochemistry 32: 25-33.
- Liew H. J., Ambak M. A., Abol-Munafi A. B., Chuah T. S., 2006 Embryonic development of clownfish *Amphiprion ocellaris* under laboratory conditions. Journal of Sustainability Science and Management 1(1): 64-73.
- Madhu R., Madhu K., Venugopal K. M., 2010 Sex change of hatchery produced *Amphiprion ocellaris*: influence of mating system removal on gonad maturation and nesting success. Journal of the Marine Biological Association of India 52(1): 62-69.
- Militz T. A., Foale S., 2017 The "Nemo effect": perception and reality of *Finding Nemo's* impact on the marine aquarium fisheries. Fish and Fisheries 18(3): 596-606.

- Miura S., Komatsu T., Higa M., Bhandari R. K., Nakamura S. Nakamura M., 2003 Gonadal sex differentiation in protandrous anemone fish, *Amphiprion clarkii*. *Fish Physiology and Biochemistry* 28: 165-166.
- Miura S., Nakamura S., Kobayashi Y., Piferrer F., Nakamura M., 2008 Differentiation of ambisexual gonads and immunohistochemical localization of P450 cholesterol side-chain cleavage enzyme during gonadal sex differentiation in the protandrous anemonefish, *Amphiprion clarkii*. *Comparative Biochemistry and Physiology, Part B* 149(1): 29-37.
- Moyer J. T., Nakazono A., 1978 Protandrous hermaphroditism in six species of the anemonefish genus *Amphiprion* in Japan. *Japanese Journal of Ichthyology* 25(2): 101-106.
- Nakamura M., Kobayashi Y., Miura S., Alam M. A., Bhandari R. K., 2006 Sex change in coral reef fish. *Fish Physiology and Biochemistry* 31(2-3): 117-122.
- Navarro-Martín L., Blázquez M., Piferrer F., 2009 Masculinization of the European sea bass (*Dicentrarchus labrax*) by treatment with an androgen or aromatase inhibitor involves different gene expression and has distinct lasting effects on maturation. *General and Comparative Endocrinology* 160: 3-11.
- Nguyen H. T. T., Tran A. N. T., Ha L. T. L., Ngo D. N., Dang B. T., Geffen A. J., 2019 Host choice and fitness of anemonefish *Amphiprion ocellaris* (Perciformes: Pomacentridae) living with host anemones (*Anthozoa: Actiniaria*) in captive conditions. *Journal of Fish Biology* 94(6): 937-947.
- Palmtag M. R., 2017 The marine ornamental species trade. *Marine Ornamental Species Aquaculture* 3-14.
- Pandian T. J., Sheela S. G., 1995 Hormone induction of sex reversal in fish. *Aquaculture* 138(1-4): 1-22.
- Pandian T. J., Kirankumar S., 2003 Recent advances in hormonal induction of sex-reversal in fish. *Journal of Applied Aquaculture* 13(3-4): 205-230.
- Papoulias D. M., Noltie D. B., Tillitt D. E., 2000 Effects of methyl testosterone exposure on sexual differentiation in medaka, *Oryzias latipes*. *Marine Environmental Research* 51: 181-184.
- Pasmanik M., Callard G. V., 1988 Changes in brain aromatase and 5 alpha-reductase activities correlate significantly with seasonal reproductive cycles in goldfish (*Carassius auratus*). *Endocrinology* 122(4): 1349-1356.
- Phuc Thuong N., Sung Y. Y., Ambak M. A., Abol-Munafi A. B., 2017 The hormone 17 β -estradiol promotes feminization of juveniles protandrous hermaphrodite false clownfish (*Amphiprion ocellaris*). *Marine and Freshwater Behaviour and Physiology* 50(3): 195-204.
- Piferrer F., 2001 Endocrine sex control strategies for the feminization of teleost fish. *Aquaculture* 197(1-4): 229-281.
- Piferrer F., Donaldson E. M., 1991 Dosage-dependent differences in the effect of aromatizable and nonaromatizable androgens on the resulting phenotype of coho salmon (*Oncorhynchus kisutch*). *Fish Physiology and Biochemistry* 9(2): 145-150.
- Piferrer F., Baker I. J., Donaldson E. M., 1993 Effects of natural, synthetic, aromatizable, and nonaromatizable androgens in inducing male sex differentiation in genotypic female chinook salmon (*Oncorhynchus tshawytscha*). *General and Comparative Endocrinology* 91(1): 59-65.
- Pouil S., Tlustý M. F., Rhyne A. L., Metian M., 2020 Aquaculture of marine ornamental fish: overview of the production trends and the role of academia in research progress. *Reviews in Aquaculture* doi: 10.1111/raq.12381.
- Ranjan R., Xavier B., Dash B., Edward L. L., Suresh R. D., Kumar P. S., 2015 Efficacy of 17 α -methyltestosterone and letrozole on sex reversal of protogynous grouper, *Epinephelus tauvina* (Forsk., 1775) and spawning performance of sex-reversed males. *Aquaculture Research* 46(9): 2065-2072.
- Rattanayuvakorn S., Mungkornkarn P., Thongpan A., Chatchavalvanich K., 2006 Gonadal development and sex inversion in saddleback anemonefish *Amphiprion polymnus* Linnaeus (1758). *Kasetsart Journal* 40: 196-203.

- Simpson E. R., Michael M. D., Agarwal V. R., Hinshelwood M. M., Bulun S. E., Zhao Y., 1997 Cytochromes P450 11: expression of the CYP19 (aromatase) gene: an unusual case of alternative promoter usage. *FASEB Journal* 11(1): 29-36.
- Singh A. K., 2013 Introduction of modern endocrine techniques for the production of monosex population of fishes. *General and Comparative Endocrinology* 181:146-155.
- Stell S. K., Moller P., 2017 Androgen-induced pseudo-hermaphroditic phenotypes in female *Brevimyrus niger* Günther 1866 (Teleostei, Mormyridae). *Fish Physiology and Biochemistry* 43(6): 1517-1529.
- Turan F., Cek S., Atik E., 2006 Production of monosex male guppy, *Poecilia reticulata*, by 17 α -methyltestosterone. *Aquaculture Research* 37(2): 200-203.
- Wabnitz C., Taylor M., Green E., Razak T., 2003 From ocean to aquarium: the global trade in marine ornamental species. UNEP-WCMC, Cambridge, UK 64 pp.
- Wassermann G. J., Afonso L. O. B., 2003 Sex reversal in Nile tilapia (*Oreochromis niloticus* Linnaeus) by androgen immersion. *Aquaculture Research* 34: 65-71.
- Yeung L. Y., 2000 The reproductive biology of Clark's anemone-fish *Amphiprion clarkii* (Bennett 1830), in Hong Kong. Thesis dissertation. The University of Hong Kong, 124 pp.

Received: 20 February 2020. Accepted: 24 March 2020. Published online: 02 April 2020.

Authors:

Muhammad Yazed Abduh, Faculty of Fisheries and Food Sciences, Universiti Malaysia Terengganu, 21030 Kuala Nerus, Malaysia; Institute of Tropical Aquaculture, Universiti Malaysia Terengganu, 21030 Kuala Nerus, Malaysia, e-mail: abduhyazed@yahoo.com

Nguyen Phuc Thuong, Institute of Tropical Aquaculture, Universiti Malaysia Terengganu, 21030 Kuala Nerus, Malaysia; Department of Aquatic Biology and Resources Management, Faculty of Fisheries, Nong Lam University of Ho Chi Minh City, Vietnam, e-mail: npthuong@hcmuaf.edu.vn

Ambok Bolong Abol-Munafi, Institute of Tropical Aquaculture, Universiti Malaysia Terengganu, 21030 Kuala Nerus, Malaysia, e-mail: munafi@umt.edu.my

Nor Hakim Norazmi-Lokman, Faculty of Fisheries and Food Sciences, Universiti Malaysia Terengganu, 21030 Kuala Nerus, Malaysia; Fisheries and Aquaculture Centre, Institute for Marine and Antarctic Studies, University of Tasmania, Taroona, Tasmania, Australia, e-mail: lokhakim@umt.edu.my

This is an open-access article distributed under the terms of the Creative Commons Attribution License, which permits unrestricted use, distribution and reproduction in any medium, provided the original author and source are credited.

How to cite this article:

Abduh M. Y., Phuc Thuong N., Abol-Munafi A. B., Norazmi-Lokman N. H., 2020 Producing false clownfish (*Amphiprion ocellaris*) male broodstock by administering 17 α -methyltestosterone to protandrous hermaphrodite juveniles. *AACL Bioflux* 13(2): 746-759.